

# Point-of-Care Ultrasonography in Nephrology and Critical Care: A New Era of Bedside Precision

Abhilash Koratala

Division of Nephrology, Medical College of Wisconsin, Milwaukee, USA

RJCCN 2026; 2: 6-10

[www.rjccn.org](http://www.rjccn.org)

DOI: [10.66224/rjccn.2.1.35](https://doi.org/10.66224/rjccn.2.1.35)

This article is licensed under a CC By 4.0 International License.

**Keywords.** POCUS, ultrasound, nephrology, hemodynamics, critical illness

## INTRODUCTION

Point-of-care ultrasonography (POCUS), performed by clinicians at the bedside, has rapidly evolved from a niche skill practiced by early adopters into a widely recognized extension of the physical examination.<sup>1</sup> Across medicine, but particularly in nephrology and critical care, POCUS has emerged as a tool that sharpens clinical reasoning, reduces diagnostic uncertainty, and accelerates actionable decisions.<sup>2,3</sup> Once confined to procedural guidance, POCUS is being increasingly incorporated into hemodynamic assessment to guide resuscitative strategies aimed at optimizing organ perfusion. Its growing presence reflects not only technological progress, but a broader shift toward bedside physiology-centered diagnostics and management.

As the Research Journal of Critical Care Nephrology inaugurates its POCUS feature, it is an opportune moment to consider where the field stands today, how it has evolved, and where it is headed. The intersection of nephrology and critical care offers a uniquely compelling perspective: both disciplines rely on timely and accurate assessment of hemodynamics and other dynamic physiologic processes, areas in which the traditional physical examination is often insensitive. POCUS bridges this gap, enabling clinicians to discern why a patient is deteriorating and to judge whether a given intervention is likely to help or harm.

## POCUS AS AN EXTENSION OF THE PHYSICAL EXAMINATION

Traditional bedside assessment depends on indirect, externally observable or elicitable signs

of disease, such as pulmonary crackles, peripheral edema, and jugular venous distension, which often appear late in the disease course and are prone to substantial interobserver variability. Multiple studies have shown that clinicians frequently overestimate their proficiency in physical examination, while the examination itself has limited sensitivity for detecting early pathology or hemodynamic aberrations.<sup>4,5</sup> By extending the clinician's physical senses through direct visualization of internal organs, POCUS provides objective information that surpasses what can be inferred from inspection, percussion, palpation, and auscultation alone. This direct visualization markedly improves diagnostic yield and accuracy and enables quantitative assessment at the bedside. In this way, POCUS revitalizes the physical examination by adding a previously inaccessible dimension, real-time visualization. For example, with a limited number of focused views, clinicians can assess cardiac function, evaluate pulmonary aeration, interrogate venous flow patterns suggestive of elevated right-sided pressures, and identify hydronephrosis or potential sources of sepsis. Importantly, POCUS does not replace clinical judgment but rather supports it. The clinical question remains central, and each ultrasound view helps answer it with greater precision. Accordingly, POCUS represents a shift away from reliance on surrogate markers and toward direct assessment of bedside physiology.



Please cite this article as: Koratala A. Point-of-Care Ultrasonography in Nephrology and Critical Care: A New Era of Bedside Precision. RJCCN 2026; 2(1): 6-10

### USE-CASES IN NEPHROLOGY: FROM URINARY OBSTRUCTION TO HEMODYNAMICS

Nephrology has quietly emerged as one of the disciplines in which POCUS adds substantial value, in part because nephrologists routinely navigate diagnostic uncertainty and rely on nuanced clinical inference. Acute kidney injury (AKI), for example, encompasses a broad range of hemodynamic, obstructive, and intrinsic etiologies that are often difficult to disentangle using laboratory data and physical examination alone.

Bedside renal ultrasound enables rapid evaluation for hydronephrosis, identification of nephrolithiasis through acoustic shadowing or twinkle artifact, and assessment of bladder distention or Foley catheter dysfunction. In kidney transplant recipients, POCUS aids in differentiating physiologic collecting system dilation from true obstruction and facilitates detection of extrinsic compressive processes such as lymphoceles or hematomas.<sup>6</sup> Together, these assessments streamline clinical decision-making, minimize delays in care, and reduce unnecessary downstream imaging.

Beyond obstruction, POCUS can provide early clues about the chronicity of kidney disease. Findings such as increased cortical echogenicity, cortical thinning, and reduced renal size make a reversible intrinsic process less likely, helping clinicians contextualize an episode of AKI. Timely access to this information can shape the diagnostic trajectory and prevent unwarranted interventions.

Its most transformative impact lies in clarifying hemodynamic kidney injury. Bedside evaluation of cardiac function, pericardial effusion, pulmonary congestion, inferior vena cava dynamics, and venous Doppler flow patterns enables a more integrated assessment of renal perfusion and an individual patient's tolerance to fluid therapy. The increasing use of the term "hemodynamic AKI" reflects a broader recognition that kidney dysfunction commonly results from multiple mechanisms, often in combination, including low-flow states, elevated venous pressures, and impaired autoregulation, rather than an almost reflexive attribution to a "prerenal" process often equated with volume depletion and treated with intravenous fluids.<sup>7,8</sup>

Evidence from heart failure and dialysis populations shows that lung ultrasound can detect pulmonary congestion well before clinical signs become apparent, and that POCUS-guided adjustments in volume management improve blood pressure control and reduce recurrent decompensation.<sup>9,10</sup> Similarly, assessment of systemic venous congestion using hepatic, portal, intrarenal and femoral vein Doppler has been linked to increased risk of AKI, incomplete decongestion, and hospital readmissions, while improvement in these waveform patterns can be leveraged to track the effectiveness of decongestive therapy.<sup>11-3</sup>

Taken together, these applications underscore how POCUS allows nephrologists to look beyond the laboratory data and interrogate the broader cardiorenal axis, integrating information on perfusion, venous outflow, and dynamic response to therapy at the bedside.

### POCUS IN CRITICAL CARE: RAPID ANSWERS IN HIGH-STAKES SETTINGS

Point-of-care ultrasound has become an indispensable tool in critical care because it delivers rapid, repeatable physiologic insights in settings where diagnostic uncertainty carries immediate consequences. Intensivists routinely navigate scenarios ranging from rapid response activations on hospital wards to the management of complex, multi-organ failure in the intensive care unit, and the appeal of POCUS lies in its speed, portability, and capacity for iterative bedside assessment. In patients presenting with undifferentiated shock, POCUS helps clarify whether circulatory collapse is driven by reduced cardiac output, obstructive physiology, distributive vasodilation, or profound hypovolemia, distinctions that are essential because early therapeutic pathways diverge sharply depending on the underlying mechanism.<sup>14</sup> Further, ultrasound guidance is well known to enhance the safety and accuracy of routine procedures, including vascular access, thoracentesis, and paracentesis.

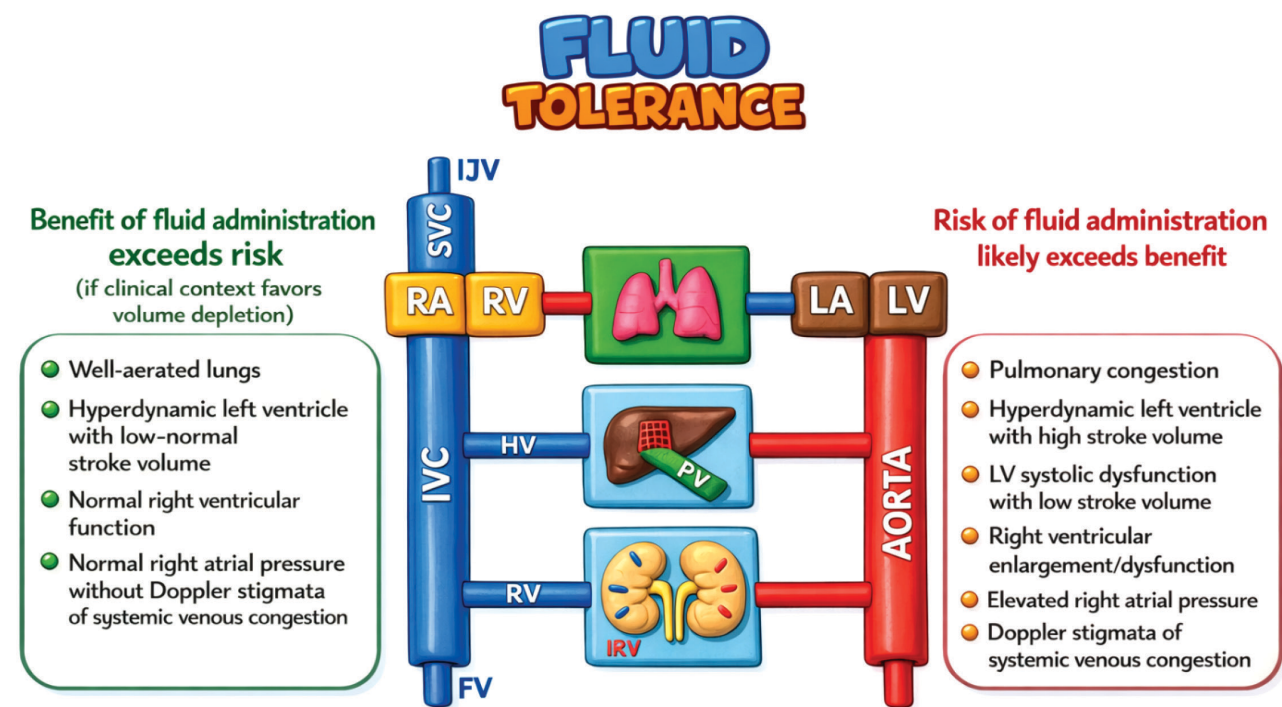
Bedside cardiac ultrasound allows rapid evaluation of left ventricular function, right ventricular strain, pericardial effusion with tamponade physiology, and gross valvular abnormalities, enabling clinicians to quickly prioritize interventions. Visual estimation of

myocardial contractility provides immediate, actionable information, while more quantitative measures such as left ventricular outflow tract velocity–time integral permit serial tracking of cardiac output trends and response to therapy. Complementing this cardiac assessment, lung ultrasound has emerged as a cornerstone of bedside respiratory evaluation, consistently outperforming auscultation and chest radiography in the detection of pulmonary edema, pneumothorax, and consolidation. The presence, distribution, and morphology of B-lines offer granular insight into thoracic fluid tolerance and the underlying etiology, helping guide management decisions.<sup>15</sup>

With respect to the common ICU dilemma of volume assessment, more accurately described as *hemodynamic evaluation*, reliance on inferior vena cava ultrasound alone is increasingly recognized as insufficient. Instead, comprehensive Doppler-based assessment of the entire hemodynamic circuit is emerging as a critical bedside skill. This approach helps determine which intervention a given patient

is most likely to benefit from, including fluid administration, vasoactive agent support, diuretics, or ultrafiltration, and allows clinicians to monitor the response to these therapies over time. Such an integrative assessment includes estimation of stroke volume, evaluation of left ventricular filling pressures and right ventricular systolic pressure, and assessment of systemic venous congestion using Doppler interrogation of hepatic, portal, and intrarenal veins, commonly referred to as the Venous Excess Ultrasound framework.<sup>16,17</sup>

One of the most important conceptual advances enabled by POCUS-guided care is the distinction between fluid responsiveness and fluid tolerance (Figure). Fluid responsiveness addresses whether stroke volume or cardiac output will increase following fluid administration, whereas fluid tolerance asks whether the patient can safely accommodate that volume without harm.<sup>18</sup> Traditional resuscitation strategies have emphasized the former, often at the expense of the latter, effectively treating fluid responsiveness as a



**POCUS-based Assessment of Fluid Tolerance**

Integrated cardiac, pulmonary, and venous ultrasound findings are used to weigh the potential benefit versus risk of fluid administration. Favorable fluid tolerance is suggested by well-aerated lungs, preserved right ventricular function, and absence of venous congestion, whereas pulmonary congestion, ventricular dysfunction, elevated right atrial pressure, and Doppler evidence of systemic venous congestion indicate limited fluid tolerance and higher risk from additional fluids.

Abbreviations: RA, right atrium; RV (yellow), right ventricle; LA, left atrium; LV, left ventricle; IJV, internal jugular vein; SVC, superior vena cava; HV, hepatic vein; RV (blue), renal vein; FV, femoral vein; IRV, intrarenal vessels.

mandate for continued fluid loading. However, emerging evidence highlights that even fluid-responsive patients may experience adverse effects from additional fluids due to venous congestion, capillary leak, and impaired lymphatic drainage. The concept of fluid tolerance reframes resuscitation by shifting attention upstream to the venous side of the circulation and the vulnerability of individual organs to congestion-related dysfunction. Through bedside assessment of cardiopulmonary interactions and early sonographic markers of congestion, POCUS offers a practical means to identify patients who are fluid responsive but no longer fluid tolerant, allowing clinicians to individualize resuscitation strategies that preserve tissue perfusion while minimizing fluid-induced organ injury.

Further, POCUS provides rapid, bedside physiologic assessment across multiple organ systems that complements clinical examination. For example, diaphragm ultrasound enables noninvasive evaluation of diaphragmatic excursion and thickening, offering insight into respiratory muscle function during acute respiratory failure, ventilator weaning, and detection of ventilator-associated diaphragmatic dysfunction. Ocular ultrasound, particularly measurement of the optic nerve sheath diameter, serves as a practical adjunct for identifying patients at risk of elevated intracranial pressure when invasive monitoring is unavailable. During cardiac arrest and peri-arrest states, POCUS facilitates the rapid identification of potentially reversible causes including tamponade, massive pulmonary embolism, severe hypovolemia, and tension pneumothorax while also assisting in confirmation of cardiac activity and guiding resuscitative priorities without delaying chest compressions. In parallel, focused abdominal sonography for trauma (FAST) remains a cornerstone for the rapid detection of pericardial, pleural, and intraperitoneal free fluid in hemodynamically unstable patients. Additionally, bedside venous compression ultrasound adds important diagnostic value in the ICU by allowing rapid detection of deep vein thrombosis, reinforcing the likelihood of pulmonary embolism when CT chest imaging is delayed but right heart strain is present on cardiac ultrasound, thereby guiding timely therapeutic decisions.<sup>19,20</sup>

## THE COMPETENCY GAP AND THE PATH FORWARD

Despite growing interest, POCUS training remains heterogeneous, with many clinicians relying on fragmented exposure through short courses or self-directed learning, an imbalance that is particularly evident in nephrology, where clinical demand has outpaced formal training infrastructure. Recent position statements underscore that competency requires not only image acquisition and interpretation but also disciplined clinical integration and an appreciation of limitations. Addressing these gaps will require intentional, multispecialty collaboration across nephrology, critical care, emergency medicine, anesthesia, and cardiology, leveraging shared expertise rather than siloed ownership of ultrasound domains. As technology continues to evolve and research increasingly refines physiologic phenotyping, the central challenge is no longer demonstrating that POCUS enhances care, but ensuring it is used consistently, safely, and meaningfully. Structured curricula, supervised longitudinal scanning, image archiving, and quality assurance must therefore become collective priorities, allowing POCUS to mature from an individual skillset into a shared clinical language that supports nuanced, physiology-driven decision-making at the bedside.

## REFERENCES

1. Díaz-Gómez JL, Mayo PH, Koenig SJ. Point-of-Care Ultrasonography. *N Engl J Med*. 2021;385(17):1593-1602.
2. Hobbs H, Millington S, Wiskar K. Multiorgan Point-of-Care Ultrasound Assessment in Critically Ill Adults. *J Intensive Care Med*. 2024;39(3):187-195.
3. Koratala A, Kazory A. An Introduction to Point-of-Care Ultrasound: Laennec to Lichtenstein. *Adv Chronic Kidney Dis*. 2021;28(3):193-9
4. Roelandt JR. The decline of our physical examination skills: is echocardiography to blame? *Eur Heart J Cardiovasc Imaging*. 2014;15(3):249-52.
5. Vukanovic-Criley JM, Criley S, Warde CM, Boker JR, Guevara-Matheus L, Churchill WH, et al. Competency in cardiac examination skills in medical students, trainees, physicians, and faculty: a multicenter study. *Arch Intern Med*. 2006;166(6):610-6.
6. Koratala A, Bhattacharya D, Kazory A. Point of care renal ultrasonography for the busy nephrologist: A pictorial review. *World J Nephrol*. 2019;8(3):44-58.
7. Panwar R, McNicholas B, Teixeira JP, Kansal A. Renal perfusion pressure: role and implications in critical illness. *Ann Intensive Care*. 2025;15(1):115.

8. Husain-Syed F, Gröne HJ, Assmus B, Bauer P, Gall H, Seeger W, et al. Congestive nephropathy: a neglected entity? Proposal for diagnostic criteria and future perspectives. *ESC Heart Fail.* 2021;8(1):183-203.
9. Beshara M, Bittner EA, Goffi A, Berra L, Chang MG. Nuts and bolts of lung ultrasound: utility, scanning techniques, protocols, and findings in common pathologies. *Crit Care.* 2024;28(1):328.
10. Reisinger N, Koratala A. Current opinion in quantitative lung ultrasound for the nephrologist. *Curr Opin Nephrol Hypertens.* 2023;32(6):509-14.
11. Argaiz ER. VExUS Nexus: Bedside Assessment of Venous Congestion. *Adv Chronic Kidney Dis.* 2021;28(3):252-61.
12. Koratala A, Argaiz ER. Femoral Vein Doppler for Guiding Ultrafiltration in End-Stage Renal Disease: A Novel Addition to Bedside Ultrasound. *CASE (Phila).* 2024;8(10):475-83.
13. Saadi MP, Silvano GP, Machado GP, Almeida RF, Scolari FL, Biolo A, et al. Modified Venous Excess Ultrasound: A Dynamic Tool to Predict Mortality in Acute Decompensated Heart Failure. *J Am Soc Echocardiogr.* 2025;38(12):1129-41.
14. Yoshida T, Yoshida T, Noma H, Nomura T, Suzuki A, Mihara T. Diagnostic accuracy of point-of-care ultrasound for shock: a systematic review and meta-analysis. *Crit Care.* 2023;27(1):200.
15. Kim DJ, Sheppard G, Lewis D, Buchanan IM, Jelic T, Thavanathan R, et al. POCUS literature primer: key papers on cardiac and lung POCUS. *CJEM.* 2024;26(10):713-20.
16. Koratala A, Ronco C, Kazory A. Diagnosis of Fluid Overload: From Conventional to Contemporary Concepts. *Cardiorenal Med.* 2022;12(4):141-54.
17. Varanasi P, Bhasin-Chhabra B, Koratala A. Point-of-care ultrasonography in acute kidney injury. *Journal of Translational Critical Care Medicine.* 2024;6(2):e24-00005.
18. Kattan E, Castro R, Miralles-Aguir F, Hernández G, Rola P. The emerging concept of fluid tolerance: A position paper. *J Crit Care.* 2022;71:154070.
19. Kim DJ, Atkinson P, Sheppard G, Chenkin J, Thavanathan R, Lewis D, et al. POCUS literature primer: key papers on POCUS in cardiac arrest and shock. *CJEM.* 2024;26(1):15-22.
20. Messina A, Robba C, Bertuetti R, Biasucci D, Corradi F, Mojoli F, et al. Head to toe ultrasound: a narrative review of experts' recommendations of methodological approaches. *J Anesth Analg Crit Care.* 2022;2(1):44.

Correspondence to:

Abhilash Koratala, MD, FASN  
8701 W Watertown Plank Rd, HUB 7th floor, Room A7333,  
Milwaukee, WI 53226, USA  
ORCID ID: 0000-0001-5801-3574  
E-mail: akoratala@mcw.edu

Received January 2026